

# MODULE 3 L06

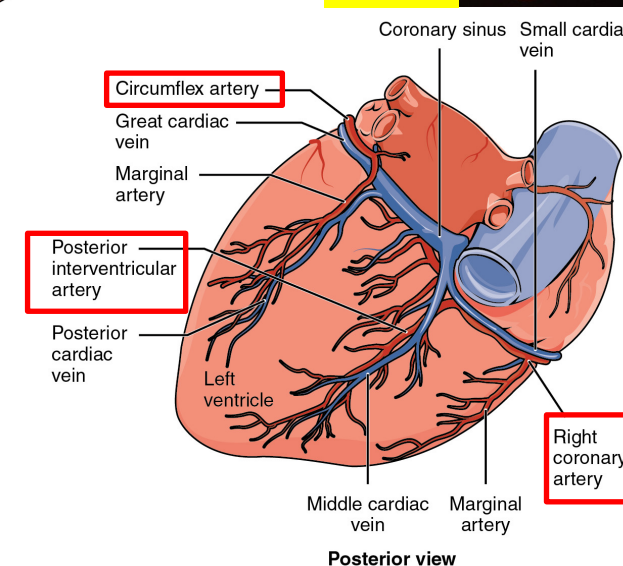
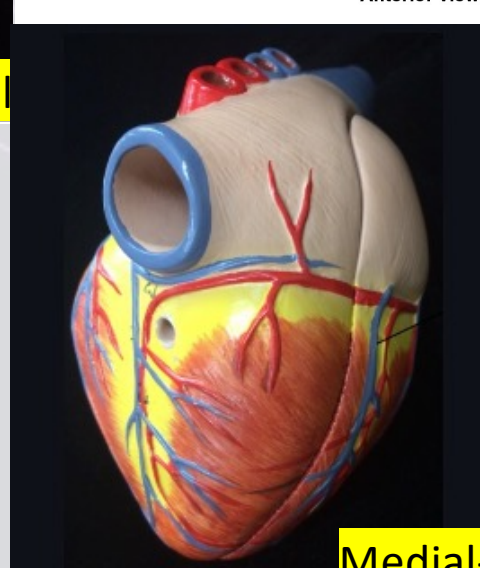
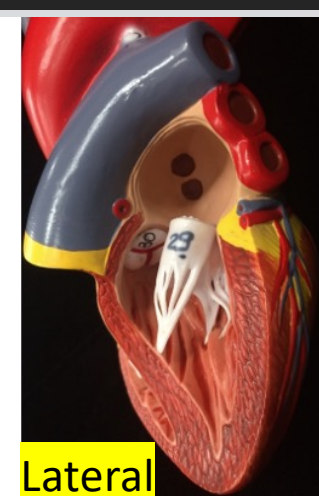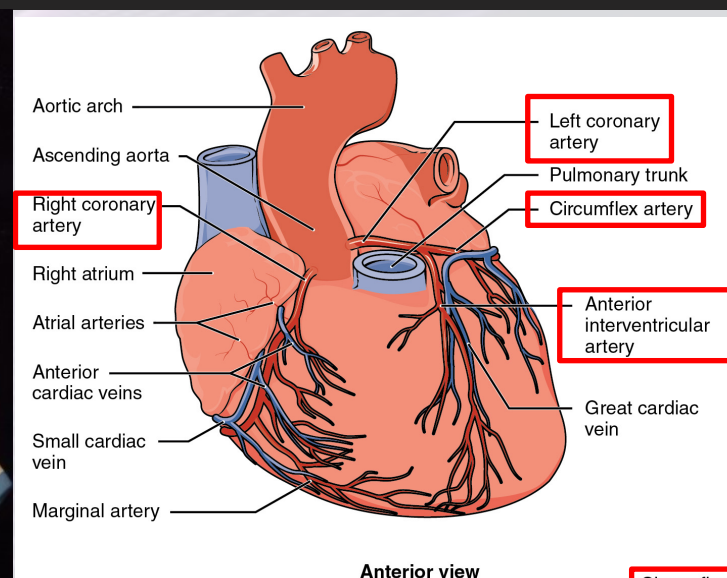
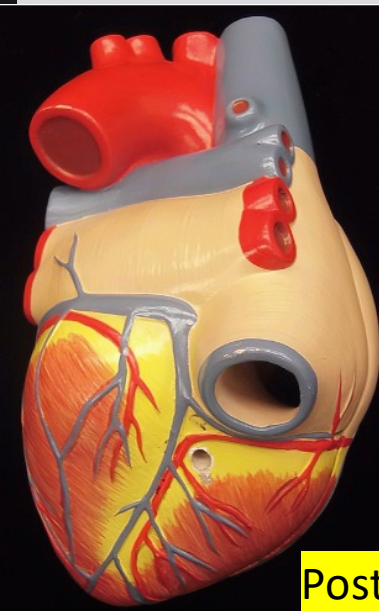
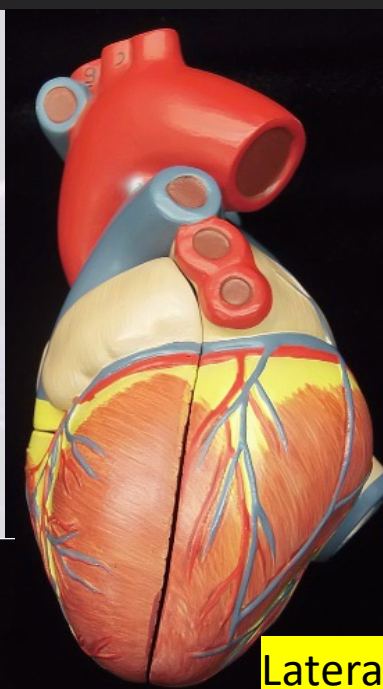

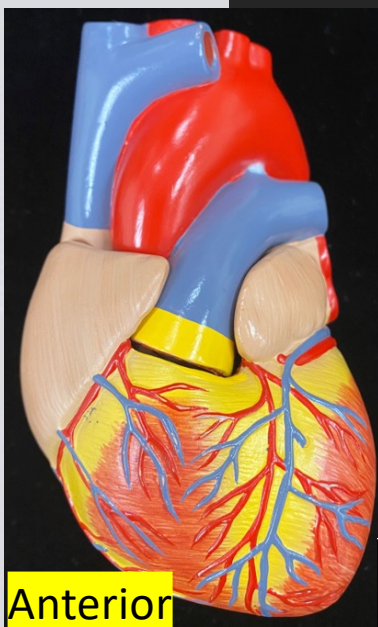
# Coronary Blood Vessels

Dr. Lisa Brinn

[lbrinn@fiu.edu](mailto:lbrinn@fiu.edu)

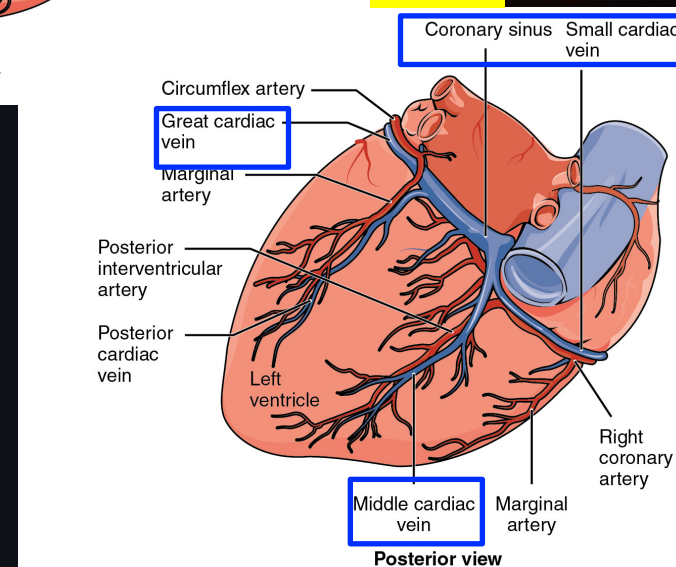
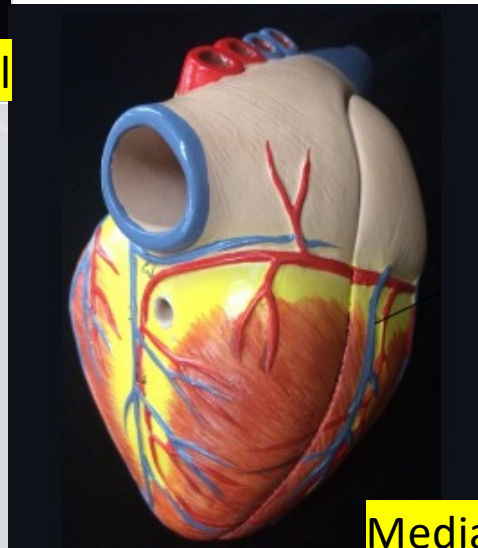
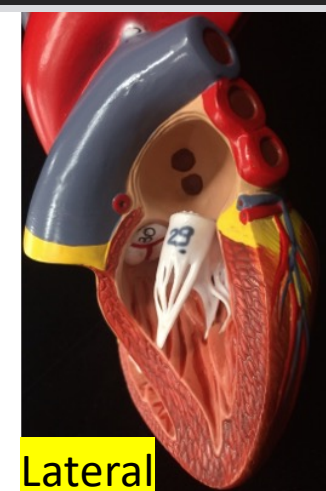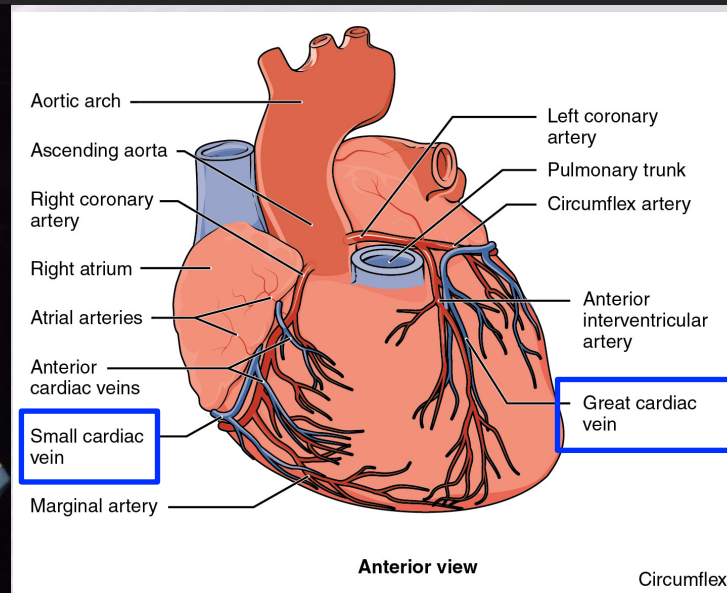
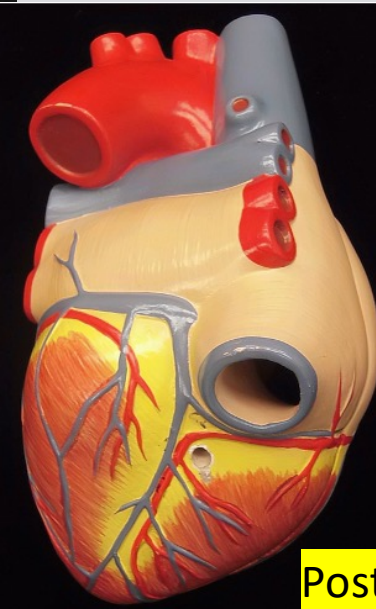
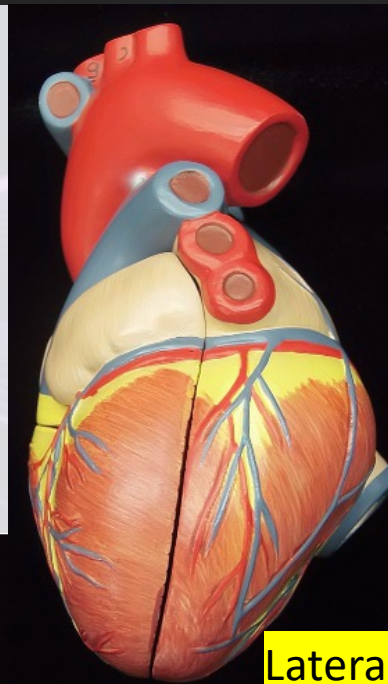

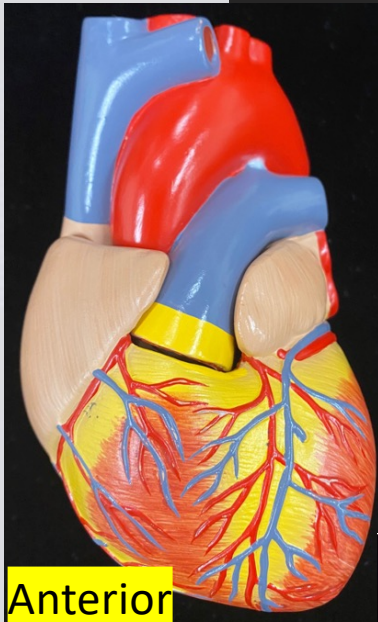


# 6. Coronary Arteries





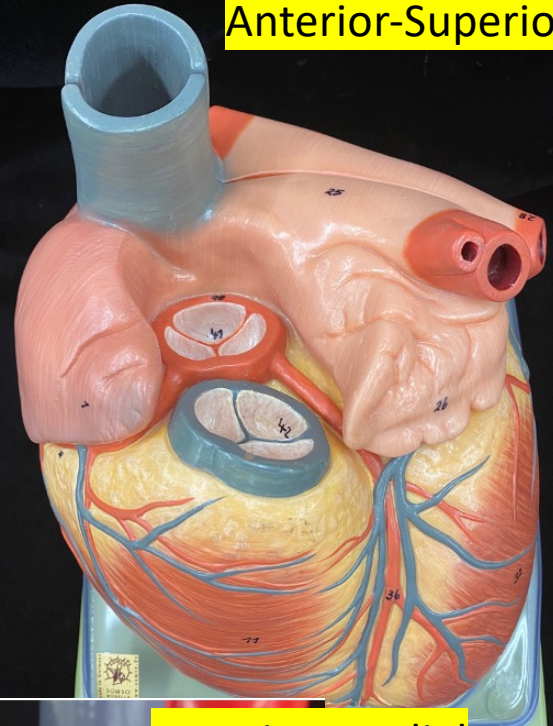
# Coronary Veins



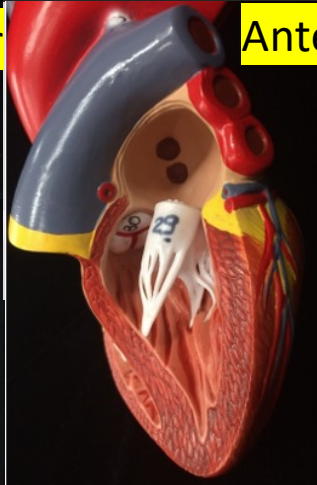


# Coronary Blood Vessels

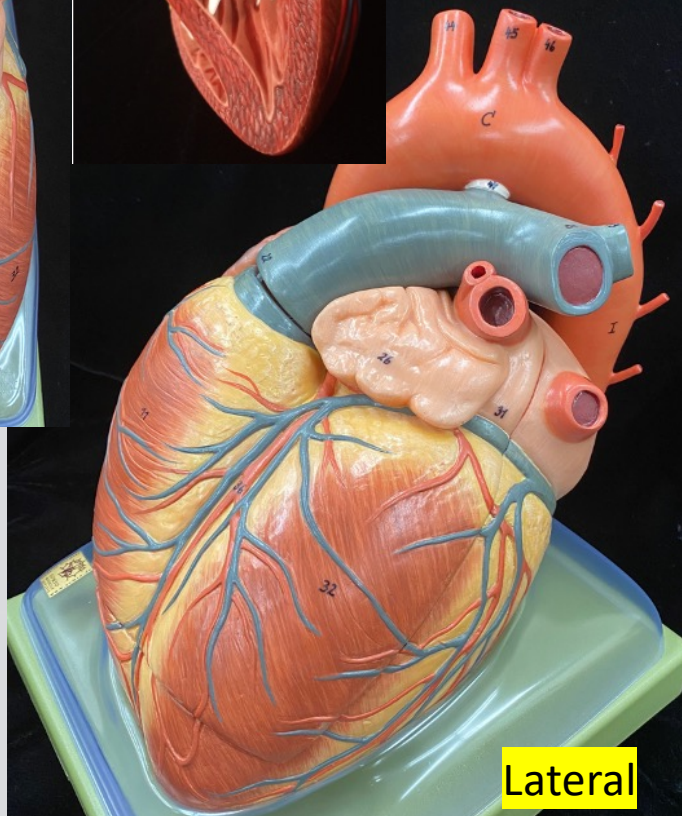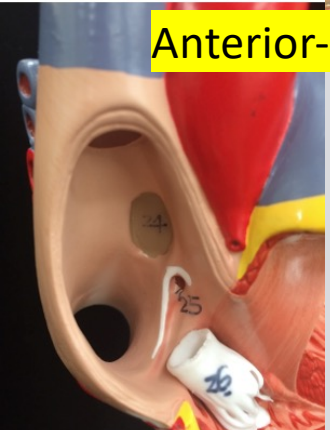Anterior-Superior



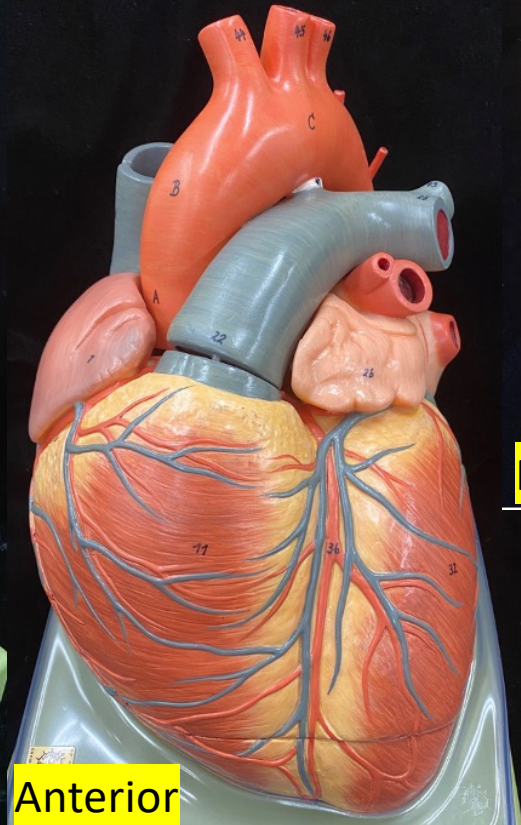
Anterior-Lateral



Anterior-Medial

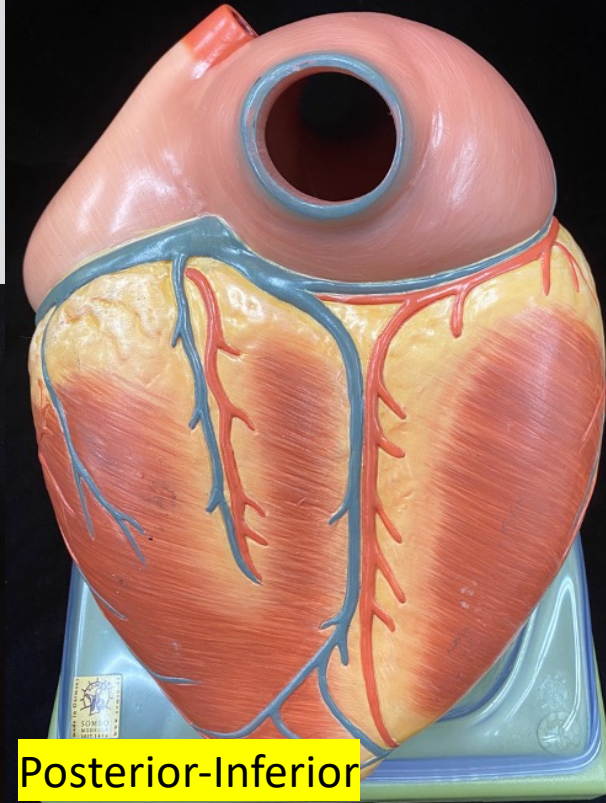


Lateral



Anterior

Posterior-Inferior



# Atherosclerotic Coronary Arteries

